

Biliary anatomy and mechanism of Biliary injury in Laparoscopic Cholecystectomy

Zafar Ullah Khan

Abstract:

Whereas laparoscopy debuted a novel era in minimally invasive surgery, its introduction in the management of gall-stone disease opened a new debate on biliary injuries. The rate of bile duct injury (BDI) in conventional cholecystectomy is around 0.2% but it varies between 0.4-0.6% with laparoscopic cholecystectomy (LC). Bile duct injury (BDI) during laparoscopic cholecystectomy can have tremendous immediate and late consequences, converting a frequently performed day-care procedure into a life-altering or terminal event. Biliary injuries can involve bile ducts, hepatic arteries and portal vein and require complex reconstructive procedures with high morbidity and mortality. The characteristic common to all biliary injuries is failure to identify ductal structures in the area of hepatocystic triangle (HCT). Tremendous efforts have been made to mitigate the risk of bile duct injury. This article is about the surgical anatomy and mechanism of injury to the biliary tree, both of paramount importance in preventing bile duct injury.

Received

Date: 3rd January, 2020

Accepted

Date : 11th November, 2020

Keywords: Laparoscopic cholecystectomy, vasculo-biliary injury, Glisson's capsule, hepatocystic triangle, critical view of safety, Rouviere's sulcus

Abbreviations: LC: laparoscopic cholecystectomy, HCT: hepatocystic triangle, CVS: critical view of safety, BDI: bile duct injury, RS: Rouviere's sulcus, VBI: vasculo-biliary injury

**Bolan Medical College,
Quetta, Pakistan**
ZU Khan

Correspondence:

Dr. Zafar Ullah Khan
Department of General
Surgery, Bolan Medical
College, Quetta, Pakistan
Address: 10-9/3247,
Arbab Barkat Ali Road,
Deba, Quetta
Cell No: +92-336-0839995
email: zafarkhanbabar@
gmail.com

Glisson's capsule and the hepatic plate system:

Glisson's capsule and the hepatic plate system: Glisson's capsule is a thin layer of connective tissue under the peritoneal covering of the liver.^{1,2} Parenchymal extensions pass from it down to hepatic lobules. It is thickened at various places forming a system of 'plates'. It is called the 'hilar plate' at the hilum of the liver encapsulating the biliary ducts, hepatic arteries and portal venous branches. The 'cystic plate' is the white, loose areolar tissue separating the posterior wall of the gallbladder from the liver.^{3,4} Small bile ducts, 1-2mm in size, the so-called 'ducts of Luschka', may course through it and enter the posterior wall of the gallbladder.^{5,6} The term 'duct of Luschka' is controversial and many authors

prefer the term 'sub-vesical duct' instead. These small ducts originate from the right hepatic lobe and course along the gallbladder fossa.⁷

Schnelldorfer⁸ has classified sub-vesical ducts into four types:

1. Segmental or sectoral subvesical duct: the right posterior segmental or sectoral duct that runs in the gallbladder fossa draining into the main duct. Common variant.
2. Accessory segmental or sectoral subvesical duct: an accessory right posterior segmental or sectoral duct that runs in the gallbladder fossa draining into the main duct. Most common variant.

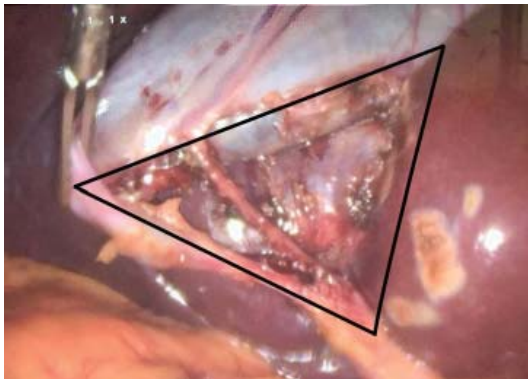


Figure 1: Hepatocystic triangle after attaining complete CVS.

3. Hepato-cholecystic duct: drains directly into the gallbladder. Very rare variant.
4. Aberrant sub-vesical duct: a network of bile ducts embryologically connected to hepatic ducts but end blindly in the connective tissue around the gallbladder. Rare variant.

Gallbladder: Gallbladder, liver and extrahepatic bile ducts are derived from the primitive foregut. Gallbladder lies in the cystic fossa underlying the liver. It is covered with peritoneum except posteriorly where 'cystic plate' separates it from the liver.⁶ It is divided into fundus, body, infundibulum and neck. The neck tapers into the cystic duct which enters the common hepatic duct forming the bile duct. A diverticulum-like 'Hartmann's pouch' develops pathologically due to the presence of stones in the infundibulum and neck.⁹ It may be adherent with the bile duct and obscure the cystic duct during cholecystectomy, thus putting the bile duct at risk of injury.¹⁰

Hepato-cystic triangle: Used interchangeably with Calot's triangle, the hepatocystic triangle (HCT) is bordered by the cystic duct, common hepatic duct and visceral surface of liver.^{11,12} It is covered by a double layer of peritoneum containing fatty tissue, lymphatics and autonomic nerves. The right hepatic and cystic arteries and anomalous structures are commonly located in it. Knowledge of anatomical variations in this area has critical importance in biliary surgery. Dissection of the fibrofatty tissue in HCT is key to achieving a critical view of safety (CVS)

during LC. Although HCT has also been mentioned as cystohepatic triangle of Calot,^{6,11} the author prefers to call it 'cholecystohepatic triangle' since gallbladder forms part of its inferior border once a complete CVS has been achieved.

Cystic Duct: The 2-4 cm long cystic duct arises from the gallbladder neck and joins the common hepatic duct near the porta hepatis forming the bile duct. It contains the 'valves of Heister' allowing one-way entry of bile into the gallbladder. It may drain directly into the right hepatic duct or pass behind the common hepatic duct to enter its posterior or medial wall. Occasionally, a 10-12cm long cystic duct descends in the hepatoduodenal ligament to run along, spiral around or be fused with the common hepatic duct before inserting in it at a variable distance from the sphincter of Oddi.^{5,9-11} In chronic cholecystitis, the gallbladder is shrunken, thickened and fibrotic. The cystic duct may become shortened due to inflammatory contraction, fusing the infundibulum and the gallbladder neck with the bile duct. This puts the bile duct at risk of injury being mistaken for cystic duct. Occasionally, the right posterior or anterior segmental duct enters the cystic or right hepatic duct as a developmental anomaly. This is misleadingly called an accessory cystic duct.^{8,10,13} Cystic duct stump is a common source of post-cholecystectomy bile leak, followed by subvesical ducts.^{8,14,15}

Cystic artery: It arises from right hepatic artery after the latter has passed behind the common hepatic duct. It divides into superficial and deep branches on gallbladder neck.⁵ Knowledge of vascular variations in this region is of paramount importance to avoid injury to these vessels and subsequently to biliary tree while securing hemostasis. Cystic artery arises from the right hepatic, left hepatic, common hepatic, gastroduodenal, celiac and superior mesenteric artery among other rarer origins. Accessory cystic artery arises from common hepatic artery or one of its branches. In 20% cases, it arises from right hepatic artery but runs anterior to common hepatic duct.⁹ It is found inside HCT in 81.5% cases and outside HCT in 4.9% cases, coursing below cystic duct.^{9,17} It may be short in 9.5%

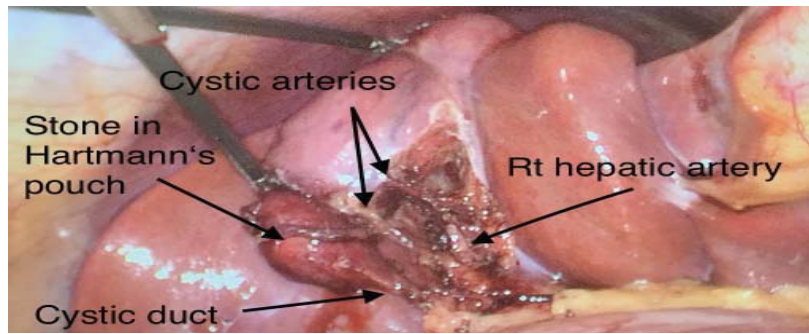


Figure 2: CVS exposing doublet cystic arteries

cases. Multiple cystic arteries exist in 8.9% cases. Right hepatic artery arises from hepatic artery proper. It may arise from superior mesenteric artery which may also give rise to an accessory right hepatic artery. Right hepatic artery may form a loop near the gallbladder neck called 'the caterpillar' or 'Moynihan hump'. Cystic artery originates from the apex of this hump risking the right hepatic artery while clipping the cystic artery. Right hepatic artery passes between common hepatic duct and portal vein. It may pass behind portal vein or in front of common hepatic duct where it can be mistaken as cystic artery.^{5,10,11}

Bile ducts: Interlobular canaliculi join to form segmental bile ducts.¹⁰ Ducts from segments VI and VII form the right posterior sectoral duct lying horizontally along the cystic fossa. The more vertical right anterior sectoral duct is formed by the confluence of ducts from segments V and VIII. Ducts from segments II, III, IV form the left hepatic duct at the base of umbilical fissure.⁹ Left hepatic duct courses transversely deep to hilar plate before entering liver, making it more accessible during surgery.¹⁰ Segment I has its own biliary drainage into both or any of the right or left hepatic ducts.¹⁷ At hilum, right and left hepatic ducts form the confluence of bile ducts. Anatomical variations of biliary tree are common and a normal pattern is seen in less than 60% of individuals. In 57%, right anterior and posterior sectoral ducts join to form right hepatic duct. In the remainder, these segmental ducts join the confluence individually. Right posterior sectoral duct may join either common hepatic or cystic duct in 6% of individuals, a fact

of surgical importance.⁹

Extrahepatic ducts lie within the hepatoduodenal ligament. Common hepatic duct descends from the confluence and is joined by cystic duct forming the bile duct. Cystic duct joins the confluence directly in 2% of individuals. It runs along common hepatic duct in 15-20% cases and joins it behind the duodenum.^{9,10} Bile duct descends in hepatoduodenal ligament anterior to portal vein and lateral to hepatic artery proper. It passes behind the first part of duodenum and head of pancreas to enter the medial wall of second part of duodenum. Here, it is joined by the major pancreatic duct and both the ducts open at the ampulla of Vater.⁵ Common hepatic and bile ducts are supplied by arteries originating from right hepatic, gastroduodenal and retroduodenal arteries. Main arteries supplying the bile duct descend at 3 and 9 o'clock positions forming the epi-choledochal plexus, a marker of bile duct identification during cholecystectomy. Extensive dissection around bile duct can disrupt the plexus and impair its blood supply.^{9,11}

Rouviere's sulcus: It's a naturally occurring cleft on the inferior surface of the right lobe of the liver.¹⁸ Rouviere's sulcus (RS) is used as an extra-biliary reference point to keep dissection above this level in LC. It is found in around 80% cases and is approximately 2-3cm long, 1cm deep and 1cm wide. Containing the right portal pedicle, it extends to the right from the porta-hepatis, anterior to segment I of the liver. The Rouviere's sulcus may be open throughout its length and the right hepatic pedicle can be seen in it. It may be closed at its medial end or exist as a slit or a scar. The Rouviere's sulcus is absent in 20% of individuals and may not be identifiable in diseased livers.¹⁹ It is surgically important because it indicates the plane and upper limit of the bile duct during LC. The dissection in HCT should always stay above the horizontal plane of Rouviere's sulcus to avoid an injury.^{20,21} The gallbladder neck lies at the level of Rouviere's sulcus, the cystic duct and artery lie above it and the bile duct below it.¹⁹ The Rouviere's sulcus is distorted in cirrhosis, fatty liver or chronic cholecystitis, rendering it a less useful guide. In these

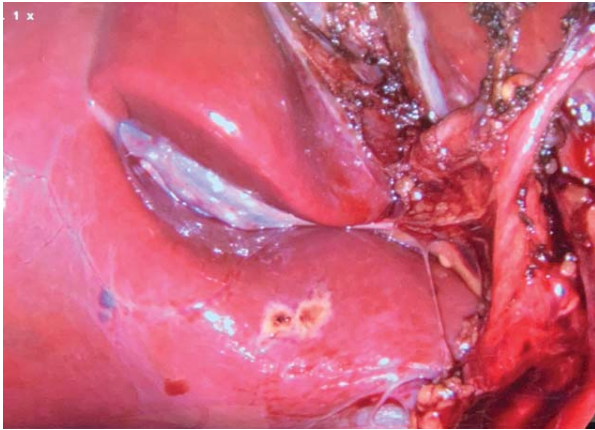


Figure 3: Rouviere's sulcus. Note the dissection limited anterior to the sulcus.

conditions, the surgeon must resort to achieving a CVS without using Rouviere's sulcus.^{19,21}

Mechanism of biliary injury: The mechanism of BDI has been extensively studied.^{13,22,23} It occurs mainly because of human error due to visual misperception, cognitive fixation, psychological factors and a variable ductal anatomy causing mis-identification of structures in the hepatocystic triangle (HCT).^{13,23,24} Mis-identification of structures is also related to anatomic distortion caused by inflammation, fibrosis and aberrant anatomy. This creates a perceptual illusion of structures in the HCT. The common hepatic or bile duct may be mistaken as the cystic duct and clipped and divided.¹³ With further proximal dissection, the common hepatic duct is mistaken for an accessory cystic duct and is divided.^{13,24} The right or left hepatic duct and right hepatic artery may also be injured during this process. Excessive traction on the cystic duct may tent the bile duct so that a portion of it is clipped and removed causing a narrowing of its lumen. Other mechanisms of bile duct injury include excessive use of cautery near the bile duct, over-judicious use of clips to control bleeding, presence of sub-vesical ducts, mistaking an aberrant or low inserting right hepatic duct for cystic duct, inadequately occluding the cystic duct while clipping it, mistaking right hepatic artery for cystic artery and ligating it, and a cystic artery coursing lateral to the cystic duct. Additionally, the relationship of the cystic duct to hepatic and bile ducts may be distorted

by inflammatory fusion of structures leading to anatomical mis-perception.^{13,23,25} Factors contributing to biliary injury include lack of experience in laparoscopic surgery, lack of experience in open surgery creating a fear of conversion and prompting the surgeon to continue with laparoscopy beyond his skills and safe limits. Impatience, hurriedness, over-confidence on laparoscopic skills and lack of routine use of intra-operative cholangiography contribute to biliary injury.^{23,24}

Bile duct injury can be coupled with severe vascular injuries in difficult gallbladders, especially in fundus-first dissection.²⁶

Injury to right hepatic artery, hepatic artery proper, common hepatic artery, right portal vein and main portal vein have been reported.^{2,26-28} Complete transection of the hepatoduodenal ligament and injury to duodenum and colon may also occur.²⁶ The right hepatic artery is more commonly injured along with right hepatic duct resulting in slow infarction of the liver in 10% cases.²⁹ Injury to hepatic artery proper leads to diffuse necrosis of the biliary tree extending to intrahepatic biliary radicals.²⁶ Injury to the main portal vein, common or proper hepatic artery are less common but can lead to rapid liver infarction.²⁹ These vascular injuries may end up in right hepatectomy or even liver transplantation.^{30,31} The mechanism behind these injuries is as follows. The hepatic plate ensheathes the right and left portal pedicles as they enter the liver. The medial end of the cystic plate is continuous with the sheath of right portal pedicle. In severe inflammatory scarring, the cystic plate is contracted, thickened and shortened, drawing the gallbladder neck closer to the right portal pedicle. The plane between gallbladder and cystic plate is obliterated making it hard to define the exact plane of dissection. This jeopardizes the right portal pedicle during dissection around the gallbladder neck and severe vascular injury can occur, especially when fundus-first technique is used for cholecystectomy.²⁶ The surgeon must recognize the danger and resort to a subtotal rather than total cholecystectomy in order to avoid a severe injury.^{32,33}

Conclusion:

Cholecystectomy is a commonly performed procedure. Biliary injuries are rare but have serious consequences. Clearly, prevention is the most effective means of addressing these injuries. A thorough knowledge of biliary anatomy, careful dissection and a clear concept of the mechanism of biliary injuries is of paramount importance for performing a safe cholecystectomy. The surgeon must recognize the danger zone and use his wisdom to alter the course of operation and sail away from the danger by adopting a safer approach rather than persevering with total cholecystectomy. The safety protocol for difficult cholecystectomy highlights avoiding a total cholecystectomy and resorting to cholecystostomy or subtotal cholecystectomy if CVS cannot be achieved.

Conflict of interest: None

Funding source: None

Role and contribution of authors:

Dr. Zafar Ullah Khan collected the data, references and wrote the article.

References:

1. Ismael HN, Cox S, Cooper A, et al. The morbidity and mortality of hepaticojejunostomies for complex bile duct injuries: a multi-institutional analysis of risk factors and outcomes using NSQIP. *HPB* 2017;19(4):352-358.
2. Buell JF, Cronin DC, Funaki B, et al. Devastating and Fatal Complications Associated With Combined Vascular and Bile Duct Injuries During Cholecystectomy. *Arch Surg* 2002;137(6):703-710.
3. de Reuver PR, Sprangers MA, Rauws EA, Lameris JS, Busch OR, van Gulik TM, et al. Impact of bile duct injury after laparoscopic cholecystectomy on quality of life: a longitudinal study after multidisciplinary treatment. *Endoscopy*. 2008;40:637-643.
4. Asbun, H.J., Rossi, R.L., Lowell, J.A. et al. Bile duct injury during laparoscopic cholecystectomy: Mechanism of injury, prevention, and management. *World J. Surg* 1993;17:547-551.
5. Gray's Anatomy. Williams PL, Warwick R, Dyson M, Bannister LH, eds. 37th Ed. Churchill Livingstone; 1989: 768-770, 1389-1394.
6. Cuschieri A. 'The biliary tract'. In: Cuschieri, Giles GR, Moosa AR, eds. *Essential Surgical Practice*. 3rd Edition. Butterworth-Heinemann; 1995:1176-1179.
7. Spanos CP, Syrakos T. Bile leaks from the duct of Luschka (subvesical duct): a review. *Langenbeck's Arch Surg*. 2006;391(5):441-7.
8. T, Sarr MG, Adams DB. What is the duct of Luschka? – A systematic review. *J Gastrointest Surg*. 2012;16(3):656-662.
9. Adrian Savage. *Surgical anatomy of the liver and biliary tree*. In: Morris PJ, Malt RA, eds. *Oxford Textbook of Surgery*. 1st Ed. Vol 1. Oxford University Press; 1994:1171-1174.
10. David L. Nahrworld. The biliary system. In: Sabiston Jr. DC, Lyerly HK, eds. *Sabiston Textbook of Surgery. The Biological Basis of Modern Surgical Practice*. 15th Ed. W.B. Saunders Company; 1997:1117-1119.
11. Moore KL, Dalley AF, Agur AMR, eds. *Abdomen*. In: *Clinically Oriented Anatomy*. 8th Ed. Wolters Kluwer; 2018:501-512.
12. L.J. Skandalakis, J.E. Skandalakis (eds), *Surgical Anatomy and Technique: A Pocket Manual*, New York: Springer; 2014:361-403
13. Sonneday CJ. Complications of Biliary Surgery. In: Mulholland MW, Doherty GM, eds. *Complications in Surgery*. 2nd Ed. Wolters Kluwer; 2011:429-449.
14. Kara M. Kelpinger, Mark Bloomstone. *Anatomy and Embryology of the Biliary Tract*. *Surg Clin N Am*. 94 (2014) 203-217.
15. Spanos CP, Syrakos T. Bile leaks from the duct of Luschka (subvesical duct): a review. *Langenbecks Arch Surg*. 2006;391(5):441-447.
16. Andall RG, Matusz P, du Plessis M, et al. The clinical anatomy of cystic artery variations: a review of over 9800 cases. *Surg Radiol Anat*. 2016;38(5):529-539.
17. Castaing D. *Surgical anatomy of the biliary tract*. *HPB (Oxford)*. 2008;10(2):72-76.
18. Lazarus L, Luckrajh JS, Kinoo SM, Singh B. Anatomical parameters of the Rouviere's sulcus for laparoscopic cholecystectomy. *Eur J Anat*. 2018;22(5):389-395.
19. Lockhart S, Singh-Ranger G. Rouviere's sulcus-Aspects of incorporating this valuable sign for laparoscopic cholecystectomy. *Asian J Surg*. 2018;41(1):1-3.
20. G, Iwashita Y, Hibi T, et al. Tokyo Guidelines 2018: surgical management of acute cholecystitis: safe steps in laparoscopic cholecystectomy for acute cholecystitis (with videos). *J Hepatobiliary Pancreat Sci*. 2018;25(1):73-86.
21. Singh M, Prasad N. The anatomy of Rouviere's sulcus as seen during laparoscopic cholecystectomy: A proposed classification. *J Minim Access Surg*. 2017;13(2):89-95.
22. SM. Biliary injury in laparoscopic surgery: part 2. Changing the culture of cholecystectomy. *J Am Coll Surg*. 2005;201(4):604-611.
23. Way LW, Stewart LW, Gantert W, et al. Causes and Prevention of Laparoscopic Bile Duct Injuries. Analysis of 252 Cases from a Human Factors to Cognitive Psychology Perspective. *Ann Surg* 2003;237(4):460-469.
24. Davidoff AM, Pappas TN, Murray EA, Hilleren DJ, Johnson RD, Baker ME, et al. Mechanisms of major biliary injury during laparoscopic cholecystectomy. *Ann Surg*. 1992;215:196-202.
25. Branum G, Schmitt C, Baillie J, et al. Management of major biliary complications after laparoscopic cholecystectomy. *Ann Surg*. 1993;217(5):532-541.
26. Strasberg SM, Gouma DJ. 'Extreme' vasculobiliary injuries: association with fundus-down cholecystectomy in severely inflamed gallbladders. *HPB (Oxford)*. 2012;14(1):1-8.
27. Archer SB, Brown DW, Smith SD, et al. Bile duct injury during laparoscopic cholecystectomy: results of a national survey. *Ann Surg* 2001;234(4):549-558.
28. Madariaga JR, Dodson SF, Selby R, Todo S, Iwatsuki S, Starzl TE. Corrective treatment and anatomic considerations for laparoscopic cholecystectomy injuries. *Journal of the American College of Surgeons*. 1994 Sep;179(3):321.
29. Strasberg SM, Helton WS. An analytical review of vasculobiliary injury in laparoscopic and open cholecystectomy. *HPB*. 2011;13:1-14.
30. Stewart L, Robinson TN, Lee CM, Liu K, Whang K, Way LW. Right hepatic artery injury associated with laparoscopic bile duct injury: incidence, mechanism, and consequences. *J Gastrointest Surg*. 2004;8(5):523-531.
31. Laurent A, Sauvanet A, Farges O, Watrin T, Rivkine E, Belghiti J. Major hepatectomy for the treatment of complex bile duct

- injury. *Ann Surg.* 2008;248:77–83.
32. Bornman PC, Terblanche J. Subtotal cholecystectomy: for the difficult gallbladder in portal hypertension and cholecystitis. *Surgery.* 1985;98:1–6.
33. Elshaer M, Gravante G, Thomas K, et al. Subtotal cholecystectomy for “difficult gallbladders”: systematic review and meta-analysis. *JAMA Surg.* 2015;150(2):159-168.