

## CASE REPORT

**Middle ear teratoma: a rare entity**

Ehtesham Ghani, Raza Ali Shah, Adil Aziz Khan, Anwar Shah, Khaleeq Uz Zaman

**Abstract:**

Middle ear teratomas are rare benign tumors. Ten months old child presented with mass protruding out of the ear and partial seventh cranial nerve palsy. Computed Tomography(CT) scans showed that the lesion was in the middle ear and had intracranial and extra-aural extensions. The patient was operated and the lesion was completely removed. Histopathological examination revealed it to be a middle ear teratoma. Postoperatively patient remained well for one year and then he died after having recurrence.

**Keywords:** middle ear, germ cell tumour, CT scan brain, teratomas

**Introduction:**

Teratomas are the tumors that are derived from all three germ cell layers including ectoderm, mesoderm and endoderm. These may differentiate into identifiable tissues and organ.<sup>1,2</sup> Their location in head and neck is an unusual finding.<sup>3</sup> These are benign hereditary tumors which are exceptionally rare in middle ear but these do exist.<sup>4,5</sup> These should be considered in the differential diagnosis of a temporal bone mass when patient presents at birth or during childhood period.<sup>2</sup> Computed Tomography (CT) or Magnetic Resonance Imaging (MRI) are essential diagnostic tools to rule out preoperative differential diagnosis.<sup>4</sup> As a rule, these are cured by resection and do not require any adjuvant therapy.<sup>5</sup>

**Case report:**

Ten months old child presented with three weeks history of a mass protruding out from the right external auditory meatus (Figure-I). The mass was reddish brown in colour. It was associated with blood stained discharge. It was soft to firm in consistency, non-tender, non-compressible, non-reducible and non-pulsatile. It was not associated with cerebrospinal fluid (CSF) otorrhea and bony deformity. Generally patient was irritable and crying most of the times. Neurologically patient had partial 7<sup>th</sup> cranial nerve palsy.

CT scan of the head shows a lesion of mixed density (Figure -II). It was located in middle ear and extending in extra-aural area through external auditory meatus as protruding mass and intra-cranially into middle cranial fossa. It was a non-enhancing and non-calcified lesion. During surgery, the extra-aural part was removed first. The middle ear and intracranial portions were operated through retro-auricular approach. The tumor was completely removed (Figure-III). It was soft to firm in consistency and relatively vascular. Postoperatively, the patient remained well. His facial palsy initially remained same but after a period of four months it started to improve. Histologically, the extra-aural part comprised of yolk sac element with prominent stellate and spindle stroma (Figure-IV). Schiller Duval bodies and eosinophilic hyaline granules were present. The intracranial and middle ear components were compromised of all three germ layers elements including glandular and cystic structures lined by mucinous epithelium (figure-V). The fibrofatty and vascular tissues, primitive retina and heavy melanin pigmentation were also present (figure-VI). The surgery was not followed by any adjuvant therapy, as the nature of the lesion was benign. However, the child had recurrence and died one year after the surgery.

**Fauji Foundation  
Hospital Rawalpindi,  
Pakistan**

E Ghani  
RA Shah  
AA Khan  
A Shah  
KU Zaman

**Correspondence:**

Dr. Adil Aziz Khan  
House no 25, PAF Base  
Road, Askari -8,  
Chaklala, Rawalpindi.  
E-Mail Address:  
khanadil\_1@hotmail.com  
Phone Number: 0305-  
5550335

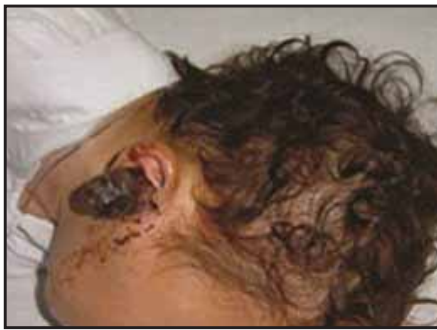

Figure 1: Photograph of the child preoperatively

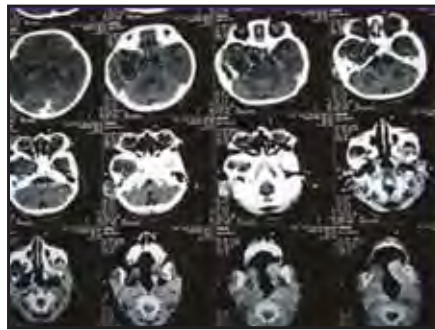


Figure 2: CT scan brain with contrast axial cuts

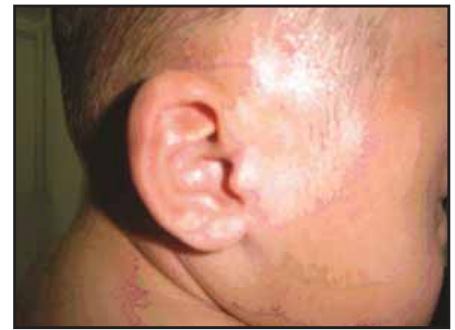

Figure 3: Photograph of the child post operatively

### Discussion:

The space occupying lesions of the middle ear range from wholly benign developmental anomalies to highly virulent and aggressive malignancies.<sup>1</sup> Teratoma of middle ear has been scarcely reported.<sup>6</sup>

Middle ear teratoma are the lesions of neonatal period and infancy.<sup>1</sup> These may be present in the new-born or in the children.<sup>3,5</sup> However, these may have late presentation as in the report by Phadke.<sup>7</sup> His patient came at the age of 25 years with sudden spurt in size of bony swelling around external ear that was present since birth. Mojabi operated upon 41 years old patient with middle ear teratoma.<sup>8</sup> In our case, the child was 10 months old and he had history of only three weeks.

Middle ear teratoma can present as bony swelling around external ear, painful swelling of the half of face, decrease visual acuity and paresis of 5<sup>th</sup>, 7<sup>th</sup> and 8<sup>th</sup> cranial nerves when there is intracranial extension.<sup>7</sup> It may present as congenital facial palsy only.<sup>3</sup> In our case, patient had extra-aural mass and partial 7<sup>th</sup> cranial nerve palsy. Moreover it may present with life threatening airway obstruction if it blocks nasopharynx while

extending through Eustachian tube.<sup>9</sup> Therefore, careful nasopharyngeal examination must be done in middle ear tumors including teratoma.

CT scan or MRI is the part of management.<sup>2</sup> The lesion is usually extra-axial mixed density.<sup>5</sup> It is limited to the middle ear if it is small.<sup>6</sup> It may extend into middle cranial fossa and infratemporal fossa.<sup>7</sup> In our case, the tumor was in the middle ear and it was extending to the middle cranial fossa and extra-aural area.

Surgery is the treatment of choice. Complete surgical resection is curative.<sup>1,8</sup> Difficulty in excision is directly related to the degree of subsequent deformation of the middle ear. It may be followed by ossiculoplasty if required. Although recurrence is rare but it can occur.<sup>4</sup> In our case, total resection was done but recurrence occurred.

Histopathology shows admixture of mature tissues representing all three germ layers including brain, myelinated nerve trunks, skeletal muscle, bone, immature cartilage, seromucinous glands, hair and respiratory epithelium.<sup>5,6</sup> Teratomas are mostly mature and benign but may contain immature and / or frankly malignant elements

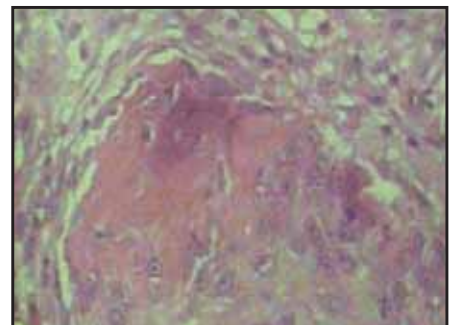
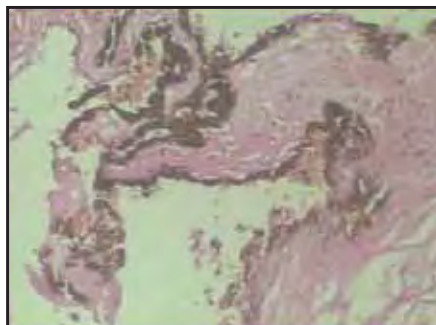
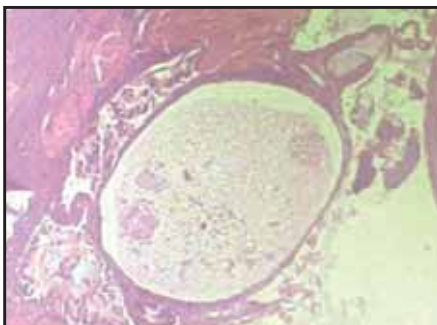


Figure 4: Photomicrographs of the tissues after histopathology

being admixed with the benign elements.<sup>7,8</sup> In our case, the components of all three germ layers were present and it was a mature teratoma. However, thorough histopathological examination of the specimen was done to exclude the possibility of immature malignant element.

#### References:

1. Devaney K, Rinaldo A, Ferlito A. teratoma of the middle ear: a real entity or a non-entity? *ActaOto-laryngologica*2005; 125: 122-4.
2. Parnes LS, Sun AH. Teratoma of the middle ear. *J Otolaryngol* 1995; 24: 165-7.
3. Navarro CM, Bonachera MD, Cassinello E, Ramos LJ, Ona EJ. Middle ear teratoma in a newborn. *JlaryngolOtol*1996; 110: 875-7.
4. Morrisseau-Durand MP, Roman S, Triglia JM, Manac'h Y. Teratoma of middle ear: a apropos of 4 new cases. *Ann Oto-laryngolChirCervicofac*1996; 113: 362-6.
5. Roncaroli F, Scheithauer BW, Pires MM, Rodrigues AS, Pereira JR. Mature teratoma of the middle ear. *OtolNeurotol*2001; 22: 76-8.
6. Inoue S, Edamatsu H, Watanabe K. A case of teratoma in the middle ear cleft with anomaly of ossicle and inner ear window. *OtolJpn*2000; 10: 206-9.
7. Phadke RS, Shenoy AS, Hosangadi A, NAdkarni TD. Mature teratoma arising from the middle cranial fossa. *Ann DiagnPathol*2004; 8: 28-31.
8. Mojabi MA. Ear teratoma: a case report. *Iran J Med Sci*2007; 32: 188-90.
9. Forest AW, Carr SJ, Beckenham EJ. A middle ear teratoma causing acute airway obstruction. *Int J PediatrOtorhinolaryngol*1993; 25:183-9.