CASE REPORT

Paraspinal abscess with epidural extension, after an anti-inflammatory non steroidal injection, in the gluteal region

Adil Aziz, Waseem Khan, Sadia khan,Sameen Shoaib

Abstract:
Spinal epidural abscess is a collection of suppurative material that forms between the dura mater and the ligamentum flavum. If not recognized early and treated correctly, it can lead to life-threatening sepsis.
We are presenting a case of a 17 year old male with history of low backache for last 3 months for which he received right intragluteal injection by a quack in his village .Patient started to develop weakness of the lower limbs after the intragluteal injection. Examination revealed paraparesis of the lower limbs.
CT scan lumbosacral spine and pelvis with contrast showed a right lower paraspinal mass with intraspinal extensions through the Rt L5/S1 neural foramen. Inferiorly the extradural component was seen exiting from the right S1 neural foramen which was also minimally expanded.On MRI lumbosacral spine, a large lobulated lesion surrounding the body and right transverse process of L5 and S1 vertebrae .The lesion was isointense to muscles on T1WS and homogeneously hyperintense on T2WS.
Psoas mass and sacral mass biopsy revealed it to be an abscess and pus was drained. After the treatment patient was pain free and gradually power improved in the lower limbs and he was able to walk without support.

Keywords: epidural abscess, anti-inflammatory non steroidal injection, gluteal region, paraspinal abscess

Introduction:
Spinal epidural abscess is a collection of suppurative material that forms between the dura mater and the ligamentum flavum. If not recognized early and treated correctly, it can lead to life-threatening sepsis.[1]

Spinal epidural abscess (SEA) was first described in the medical literature in 1761 and represents a severe, generally pyogenic infection of the epidural space requiring emergent neurosurgical intervention to avoid permanent neurologic deficits. Spinal epidural abscess comprises 0.2 to 2 cases per 10,000 hospital admissions.[2]

The existence of predisposing factors such as intramuscular injections should be considered in the assessment of suspected spinal epidural abscess.[1]

To prevent serious morbidity and mortality, early diagnosis is essential. Patients with localized back pain who are at risk for developing such epidural spinal abscesses should receive a magnetic resonance imaging scan with contrast enhancement without delay.[1]

The essential problem of SEA lies in the necessity of early diagnosis, because only timely treatment is able to avoid or reduce permanent neurologic deficits. The problem with spinal epidural abscesses is not treatment, but early diagnosis - before massive neurological symptoms occur".[2]

There is an increasing move away from surgical intervention towards conservative therapy, percutaneous drainage of abscess or both.[3]

Fauji Foundation Hospital, Rawalpindi
A Aziz
W Khan
S Khan
S Shoaib

Correspondence:
Dr.Adil Aziz Khan
House No 25, PAF Base Road, Askari -8, Chaklala, Rawalpindi.
email Address: khanadil_1@hotmail.com;
Phone Number: 0305-5550335

Case report:

A 17 year old boy presented with history of lower backache for the last 3 months for which he received an intragluteal injection by a quack in his village . After the injection the patient noticed gradual weakness of the lower limbs .On examination, the patient was unable to walk, power in the right lower limb was 2/5 from L1-L4, and 0/5 in L5-S1. Right ankle reflex was absent, sensations were absent on the right side till L1, local tenderness was present at the L5/S1 level.

All blood tests were within normal limits except ESR was 52. CT scan lumbosacral spine and pelvis, with contrast showed a right lower paraspinal mass with epidural extensions via Rt L5/S1 neural foramen (Dumb-bell shape), extending upto the level of L4-L5. CT scan appearances were suggestive of schwannoma/neurofibroma, right lower paraspinal region.(Fig:1)

On MRI lumbosacral spine, a large lobulated lesion involving the body and right transverse process of L5 and S1 vertebrae. Right sacral ala was also involved with lesion extending upto the right sacroiliac joint.The lesion was isointense to muscles on T1WS and homogeneously hyperintense on T2WS.Large lobulated mass was extending in the right posterior paravertebral region causing compression of the right psoas muscles and extension in to the right posterior paravertebral muscles which was displaced by the mass posteriorly. (Fig:2,3,4)

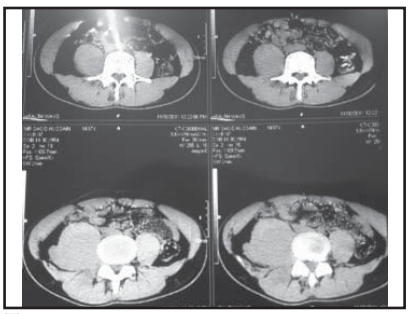

Figure 1: *CT SCAN lumbosacral spine with contrast*

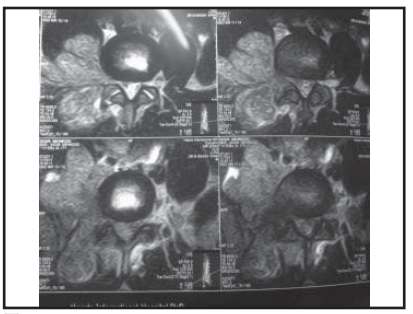

Figure 2: *MRI Lumbosacral spine with contrast axial cuts*

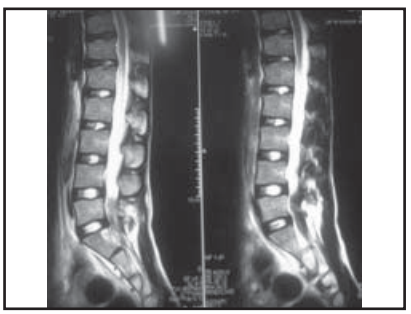

Figure 3: *MRI Lumbosacral spine ,sagital cuts, T-2 Weighted image*

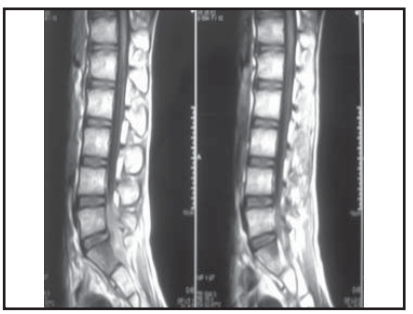

Figure 4: *MRI Lumbosacral spine,sagital cuts, T-1 Weighted image*

Exploratory laporotomy was planned and mass was biopsied but it revealed pus, which was drained. Also the Right psoas mass biopsy revealed pus, which was drained too. After drainage, the patient did not complain of backache and was kept under close follow-up in the rehabilitation department, where power in the legs gradually improved and he was able to walk without support.

Discussion:

Spinal epidural abscess is a rare clinical entity, presenting insidiously with nonspecific clinical manifestations. The diagnosis is usually difficult and, if not made early, the consequences may be disastrous.[4]

A spinal epidural abscess threatens the spinal cord or cauda equina by compression and also by vascular compromise . If untreated, an expanding suppurative infection in the spinal epidural space impinges on the spinal cord, producing sensory symptoms and signs, motor dysfunction, and, ultimately, paralysis and death. Intervention early in the course of the disease undoubtedly improves the outcome. Frequently, diagnosis is understandably delayed because the initial presentation may be only back pain. One half of cases are estimated to be misdiagnosed or have a delayed diagnosis.[5]

The frequency in large tertiary care centers is estimated to be about 2.8 cases per 10,000 admissions. The incidence is suspected to be increasing in relation to intravenous (IV) drug abuse.[6]

Clinical presentation may be quite variable. The clinical triad of fever, back pain, and neurologic deficit is not present in most patients.[7,8] Early presentations may be subtle, and atypial presentations are not unusual. A 4-phase sequential evolution has been described, with (1) localized spinal pain, (2) radicular pain and paresthesias, (3) muscular weakness, sensory loss, and

sphincter dysfunction, and finally (4) paralysis.[5]

In patients who present with worsening pain or neurological deficits following an injection, an infectious complication should remain paramount in the differential diagnosis. While an ESR or CRP may be useful screening tests in symptomatic patients, an MRI should be obtained to establish a definitive diagnosis.[9]

Conlsuion:

In a patient who has a history of such an injection followed by para and weakness, one should have high index of suspision to diagnose spinal epidural abscess. Early diagnosis with CT scan and MRI of spine and early treatment with present to prevent further worsening of condition and prompt improvement.

References:

1. Sasani M, Aydin O, Aydin AL, Oktenoglu T, Ozer AF, Ercelen O. Spinal epidural abscess as a result of dissemination from gluteal abscess secondary to intramuscular analgesic injection. Pain Pract. 2009; 9(5): 399-403.
2. Reihsaus E, Waldbaur H, Seeling W. Spinal epidural abscess: a meta-analysis of 915 patients. Neurosurgical Review. 2000; 175-204.
3. Turgut Tali E. Spinal infections. Eur J Radiol. 2004; 50: 120-3.
4. Carragoso A, Capelo J.Abcesso Epidural Vertebral A Estreptococo do Grupo C .Órgao Oficial Da Sociedade Portuguesa De Reumatologia . 2007; 32: 287-291.
5. Darouiche RO. Spinal epidural abscess. N Engl J Med. 2006; 355(19): 2012-20.
6. Prendergast H, Jerrard D, O'Connell J. Atypical presentations of epidural abscess in intravenous drug abusers. Am J Emerg Med.1997; 15(2): 158-60.
7. Joshi SM, Hatfield RH, Martin J, Taylor W. Spinal epidural abscess: a diagnostic challenge. Br J Neurosurg. 2003; 17(2): 160-3.
8. Davis DP, Wold RM, Patel RJ, et al. The clinical presentation and impact of diagnostic delays on emergency department patients with spinal epidural abscess. J Emerg Med. 2004; 26: 285-91.
9. Hooten et al. Discitis after Epidural Corticosteroid Injection. Pain Medicine. 2006; 7: 46-51.
10. Siddiq F, Chowfin A, Tight R, et al. Medical vs surgical management of spinal epidural abscess. Arch Intern Med. 2004; 164(22): 2409-12.
11. Pradilla G, Ardila GP, Hsu W, Rigamonti D. Epidural abscesses of the CNS. Lancet Neurol. 2009; 8(3): 292-300.
12. Pereira CE, Lynch JC. Spinal epidural abscess: an analysis of 24 cases. Surg Neurol. 2005; 63 Suppl 1: S26-S29.