

ROUVIERE'S SULCUS: A GUIDE TO SAFE DISSECTION IN LAPAROSCOPIC CHOLECYSTECTOMY

MUHAMMAD ZUBAIR, LUBNA HABIB*, FARZANA MEMON, MASOOM RAZA MIRZA*,
MEHMOOD A. KHAN, M. SAEED QURAI SHY

Department of Surgery, Unit IV, Dow University of Health Sciences & Civil Hospital, Karachi
Department of Surgery, Hamdard College of Medicine & Dentistry, Karachi*

ABSTRACT

Objective: To determine the frequency of Rouviere's sulcus in our population.

Study Design: Case series.

Setting & Duration: Civil Hospital Karachi and Hamdard University Hospital from November 2007 to April 2009.

Methodology: Consecutive were included patients who presented with symptomatic cholelithiasis and underwent laparoscopic cholecystectomy. Frequency and type of Rouviere's sulcus was documented in operative note. Open type of sulcus was defined as a cleft in which right hepatic pedicle was visualized and the sulcus was open throughout its length. Fused type was defined as one in which the pedicle was not visualized or if the sulcus was open only at its lateral end.

Result: A total of 160 patients who underwent laparoscopic cholecystectomy were included in the study. Open type of Rouviere's sulcus was visualized in 48 patients and 61 patients had fused type of sulcus. Hence in a total of 109 (68.13%) patients Rouviere's sulcus was visualized.

Conclusion: Rouviere's sulcus is an important extra biliary land mark, identifiable in majority of patients either as open or fused variety. Its identification before commencement of Calot's triangle dissection may help in preventing the bile duct injury.

KEY WORDS: Laparoscopic Cholecystectomy, Bile Duct Injury, Extrabiliary Land Mark, Rouviere's Sulcus, Calot's Triangle

INTRODUCTION

Laparoscopic cholecystectomy has been readily accepted and adopted by surgeons all over the world since its introduction in the late 1980s and is now the gold standard for the treatment of symptomatic cholelithiasis.^{1,2} Unfortunately, the obvious advantages for the majority of patients have been somewhat tempered due to higher risk of bile duct injury (BDI) seen in the earlier days of laparoscopic cholecystectomy.¹ Many strategies have been proposed to avoid this serious complication

of the procedure^{3,4,5} and one of these is the use of anatomical landmarks as reference points.^{2,6,7} One of the important landmarks is a sulcus which was identified by Henri Rouviere in 1924⁸ and used as a reference point to guide the commencement of safe dissection.^{2,7} It is a cleft in the liver running to the right of the hilum, anterior to caudate process which contains the right portal pedicle and accurately identifies the plane of the common bile duct.⁸ Rouviere's sulcus has been found in 78% of population in developed world.²

Keeping in view its importance for safe dissection of Calot's triangle, the aim was to determine its frequency in our population so that surgeons can utilize the benefits of this important land mark in laparoscopic cholecystectomy.

METHODOLOGY

This prospective descriptive study was conducted on 160 consecutive patients who presented with sympto-

Correspondence:

Dr. Muhammad Zubair, Senior Registrar,
Department of Surgery, Unit IV, Civil Hospital &
Dow University of Health Sciences, Karachi.
Phone: 0321-9282015.
E-mail: muhammad.zubair@duhs.edu.pk

matic cholelithiasis and underwent laparoscopic cholecystectomy from November 2007 to April 2009. Frequency and type of Rouviere's sulcus was documented. Open type of sulcus was defined as a cleft in which right hepatic pedicle was visualized and the sulcus was open throughout its length (Fig.1). Fused type was defined as one in which the pedicle was not visualized or if the sulcus was open only at its lateral end (Fig.2).

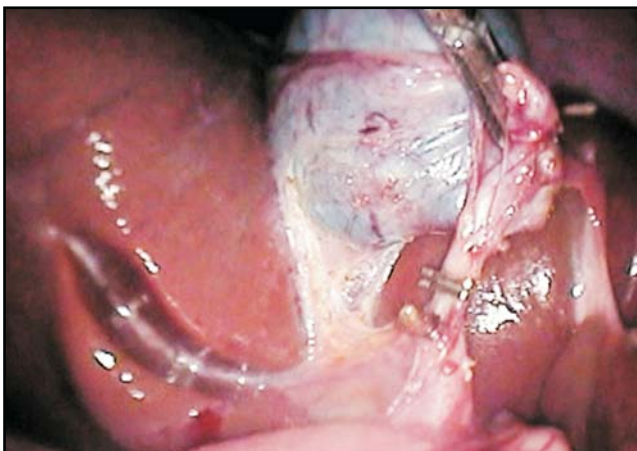
RESULTS

A total of 160 patients who underwent laparoscopic cholecystectomy were included in the study. Out of 160 patients Rouviere's sulcus was visualized in 109(68.13%) patients and in these fused type was observed in 61 (55.96%) and open in 48(44.04%) patients. 51(31.87%) patients had no sulcus.

DISCUSSION

The advantages of laparoscopic cholecystectomy have been discussed extensively in the literature. However, this technique has introduced complications which are either more complex or were not known in the era of open surgery.¹ One of the most serious complications which has been a matter of concern is bile duct injury.⁹ In initial period, laparoscopic cholecystectomy was associated with greater than 2% risk of injury to the biliary tract¹⁰ which dropped to 0.3-0.4% with increasing experience.^{7,11} Moreover, in laparoscopic era the pattern of biliary injury has become more complex and proximal (more towards the porta hepatis).³ The significant morbidity related to this technique seemed to be due to the lack of knowledge of the "laparoscopic anatomy" of the gallbladder pedicle, two dimensional vision and lack of tactile feedback.^{3,5} It is commonly thought that BDI results from imprecise dissection and poor visualization of anatomical structures¹ but despite

Fig. 1. Open type of Rouviere's Sulcus with visible right portal pedicle



enormous experience in this technique the frequency of common bile duct injury remained persistent, even in the hands of experienced surgeons.⁷

Hugh² identified some inherited factors in the procedure that uniquely predispose to surgical error and the most significant is spatial disorientation on the part of surgeon. To avoid this, he used the empiric principles developed by the maritime and aviation industries, one of which is to start from a fixed point and used Rouviere's sulcus as an extra biliary fixed point to start dissection.⁷ The importance of identifying Rouviere's sulcus lies in the fact that the cystic duct and the cystic artery lay invariably anterosuperior to the sulcus, confirming the anatomy of Calot's triangle^{7,12} (Fig. 3). Hugh and Kuldip have shown minimal incidence of common bile duct injury in their large series of laparoscopic cholecystectomy by beginning the dissection ventral to this sulcus.^{2,13} This anatomical reference point has also been used by Wu in mesohepatectomy for hepatocellular carcinoma.¹⁴ Frequency of visualization of Rouviere's sulcus is lower as compared to 90% quoted by Hugh as he included

Fig. 2. Partially fused Rouviere's Sulcus (Open at its lateral end)

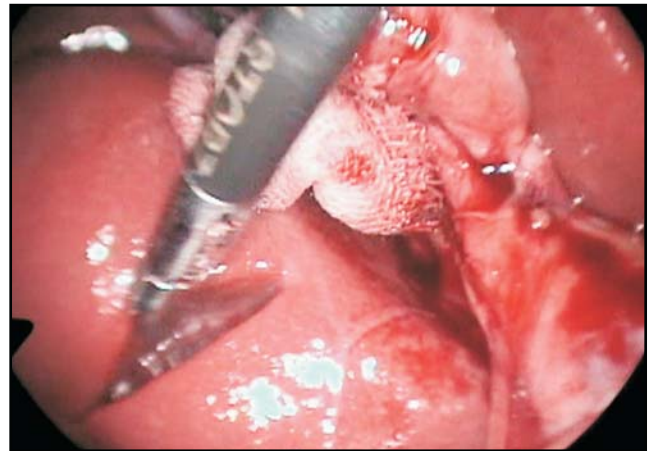
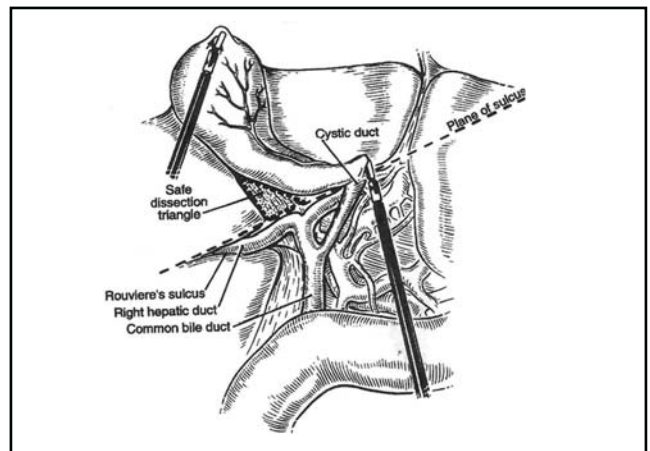


Fig. 3. Diagram showing



the white line indicating the possible area of sulcus.⁷

The authors did not consider the presence of white line only as Rouviere's sulcus because it needs experience to identify it correctly and therefore can be confusing especially in difficult cases with lot of adhesions, as in majority of patients this useful land mark is identifiable, it should be used for the commencement of safe dissection of cystic duct and artery to avoid bile duct injury.

CONCLUSION

Rouviere's sulcus is an important extra biliary land mark, identifiable in majority of patients either as open or fused variety. Its identification before commencement of Calot's triangle dissection may help in preventing the bile duct injury.

REFERENCES

- Richardson M C, Bell G, Fullarton G M. Incidence and nature of bile duct injuries following laparoscopic cholecystectomy: an audit of 5913 cases. *Br Journ Surg* 1996; 83(10): 1356-1360.
- Hugh T B, Kelly M D, Mekisic A. Rouviere's sulcus: a useful landmark in laparoscopic cholecystectomy. *Br Journ Surg* 1997; 84(9): 1253-4.
- Tebala G D, Innocenti P, Ciani R, Zumbo A, Fonsi G B, Bellini P, De Chiara F, Fittipaldi D, Hadjiamiri H, Lamaro S, Marinoni R. Identification of gallbladder pedicle anatomy during laparoscopic cholecystectomy. *Chir Ital* 2004; 56(3): 389-96.
- Hunter J G. Avoidance of bile duct injury during laparoscopic cholecystectomy. *Am Journ Surg* 1991; 162(1): 71-6.
- Hunter J G. Exposure, dissection, and laser versus electrosurgery in laparoscopic cholecystectomy. *Am J Surg* 1993; 165(4): 492-6.
- Singh K, Ohri A. Difficult laparoscopic cholecystectomy. In: Kriplani A, Bhatia P, Parsad A, Govil D, Garg H P (eds). *Comprehensive Laparoscopic Surgery*, 1st ed. New Delhi: Indian Association of Gastro Intestinal Endo Surgeons (IAGES); 2007: 77-80.
- Hugh T B. New strategies to prevent laparoscopic bile duct injury-surgeons can learn from pilots. *Surgery* 2002; 132(5): 826-35.
- Rouviere H. Sur la configuration et la signification du sillon du processus caude. *Bulletins et memoires de la societe anatomique de paris*. 1924; 94: 355-358.
- Wijsmuller A R, Leegwater M, Tseng L, Smaal H J, Kleinrensink G J. Optimizing the critical view of safety in laparoscopic cholecystectomy by clipping and transecting the cystic artery before the cystic duct. *Br Journ Surg* 2007; 94: 473-474.
- Bakhsh R, Zahid M A, Dar F S, Malik Z I, Akhtar N, Akhtar S. Iatrogenic bile duct injuries: experience at PIMS. *Journ Ayub Med Coll* 2002; 14(4): 16-8.
- Svab J, Peskova M, Krska Z, Gurlich R, Kasalicky M. Prevention, diagnosis and treatment of iatrogenic lesions of biliary tract during laparoscopic cholecystectomy. Management of papilla injury after invasive endoscopy. Part 1. Prevention and diagnosis of bile duct injuries. *Rozhl Chir* 2005; 84(4): 176-81.
- Nagral S. Anatomy relevant to cholecystectomy. *J Min Access Surg* 2005; 1(2): 53-58.
- Singh K, Ohri A. Anatomic landmarks: their usefulness in safe laparoscopic cholecystectomy. *Surg Endosc* 2006; 20(11): 1754-1758.
- Wu C C, Ho W L, Chen J T, Tang C S, Yeh D C, Liu T J, P'eng F K. Mesohepatectomy for centrally located hepatocellular carcinoma: An appraisal of a rare procedure. *Journ Am Coll Surg* 1999; 188(5): 508-15.